

Ventilation challenges in a patient with pulmonary fibrosis presenting as spontaneous bilateral pneumothoraces

M. D. James, S. A. Stayer, O. O. Olutoye

Department of Anesthesiology, Texas Children's Hospital, Houston, USA

Corresponding author: M. D. James, Department of Anesthesiology, Texas Children's Hospital, Houston, USA. Email: mdjames@texaschildrens.org

Key points

Pulmonary Fibrosis can occur in survivors of pediatric cancer. High frequency oscillatory ventilation (HFOV) and airway pressure release ventilation (APRV) may be useful in the critical care management of a pediatric patient with Pulmonary Fibrosis.

Abstract

In this report we describe difficult ventilation during anesthesia as well as in the pediatric intensive care unit in a pediatric patient with pulmonary fibrosis. We discuss how an initial diagnosis of acute spontaneous pneumothorax, a correctable problem, misdirected peri-operative planning and anesthetic management of a patient with severe pulmonary fibrosis.

Keywords: Pulmonary fibrosis, high frequency oscillation ventilation, APRV ventilation mode, neuroblastoma, pneumothorax, pediatric intensive care unit.

Introduction

Chronic pulmonary complications including radiation pneumonitis, recurrent pneumonias, pulmonary fibrosis, and spontaneous pneumothorax are known to occur following treatment for pediatric malignancies (1, 2). The patient described in this case report had a history of successful treatment for neuroblastoma ten years prior consisting of surgical resection, chemotherapy and abdominal radiation therapy. She presented with pulmonary decompensation initially diagnosed as

spontaneous bilateral pneumothoraces. We report difficulty with ventilation of this patient's lungs during two anesthetics and subsequently in the intensive care unit, as well as the eventual diagnosis and subsequent management of progressive pulmonary fibrosis.

Case report

A 13 year old, 29 kg girl presented with a 2 day history of sudden onset of dyspnea and chest pain while playing soccer. The medical history was significant for intermittent coughing for one month, and mild asthma diagnosed two years previously. Last inhaler use was 6 months prior to presentation. The patient had very mild respiratory symptoms and she was diagnosed with asthma, but the symptoms were never severe enough to warrant pulmonary function tests. Chest X-ray (CXR) revealed a large right apical pneumothorax with a left, smaller pneumothorax, apical pleural effusion and mild interstitial edema (Figure 1). She was admitted to the pediatric intensive care unit (PICU), and administered oxygen via nasal cannula to promote lung reabsorption. She was scheduled for ultrasound guided placement of bilateral pigtail catheters and computerized tomograph

of the lungs under anesthesia the next day.

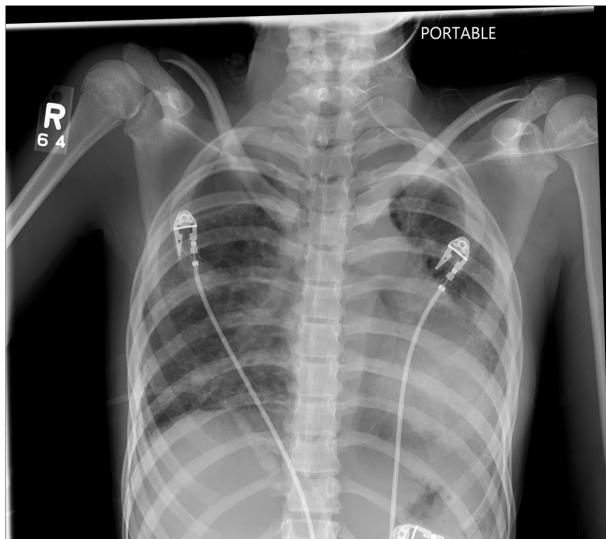


Figure 1. Admission Chest x-ray showing a large Right side Pneumothorax, Left pleural effusion at the lung apex and mild bilateral interstitial edema.

Pre-operatively, physical examination revealed a slender and lightly muscled physique girl on 3 liters nasal cannula who appeared tired, and had shallow but clear breath sounds on lung auscultation. Oxyhemoglobin saturation was 99%. Induction of anesthesia was uneventful with intravenous propofol, and anesthesia was maintained with sevoflurane in oxygen and air via a laryngeal mask airway (LMA). She received 1.7 mcg/kg of fentanyl during this 2 hour procedure but had inadequate respiratory efforts upon deep removal of the LMA which resolved after administration of naloxone. The pneumothoraces and oxygen requirement persisted so it was decided that the patient would benefit from thoracoscopic placement of standard large-bore thoracostomy tubes and a diagnostic lung biopsy. The patients room air oxyhemoglobin saturation ranged between 97-99% but she was on supplemental oxygen in order to aid re-sorption of pleural air (part of treatment algorithm for spontaneous pneumothorax). At time of second surgery, the patient was still breathing 3 L/min of oxygen via nasal cannula. She appeared fatigued but was not in respiratory distress (no tachypnea or intercostal retractions). The anesthetic plan included placement of a double lu-

men endotracheal tube (DLT) to allow thorough examination of the thoracic cavity, and to facilitate biopsies. An age-appropriate left sided double lumen tube (28 Fr) was selected for intubation. The appropriate size standard cuffed endotracheal tube (ETT) for this patient is 6.5mm and the closest size match to this is a 28Fr double lumen tube. Induction of anesthesia and tracheal intubation were uneventful and DLT placement was confirmed with fiberoptic bronchoscopy. However, a steady increase in end-tidal carbon dioxide (ETCO₂) was noted despite adjustments to the mechanical ventilator settings. In spite of oxygen saturations of 100%, the ETCO₂ values increased to 99 mm Hg, peak inspiratory pressures increased to 41 cm H₂O and maximum tidal volume was 180 mL. This poor lung compliance and hypoventilation persisted despite confirmation of the DLT position by auscultation and fiberoptic bronchoscopy, suctioning of the tube and administration of levo-albuterol. Ventilation marginally improved once surgery started with ETCO₂ values of 70-80mmHg during chest exploration. After thoracostomy tube placement, the tidal volumes increased to 230 mL, and ETCO₂ decreased to the high 50's. At the completion of the operation, the DLT was replaced with a standard endotracheal tube. Arterial blood gas values were not obtained until the patient arrived in the PICU following surgery. A CXR showed minimal improvement in expansion of both lungs despite having four thoracostomy tubes on suction. The patients oxygen saturations remained 97-100% on an inspired oxygen concentration of 100%, however, neither volume or pressure support mode of ventilation improved the patients ventilation as the high inspiratory pressure and hypercarbia persisted. At the end of surgery, a joint decision was made by the surgeon and anesthesiologist to transport the patient to the PICU and not keep her under sustained general anesthesia while trying to determine the best mode of ventilation that would suite the patients needs. Therefore, the trachea remained intubated and the patient was transported back to the PICU. Initial ventilation strategies in the

PICU consisted of conventional mechanical ventilation in both volume and pressure modes with variable amounts of positive end-expiratory pressure. Due to worsening respiratory acidosis, high frequency oscillation ventilation (HFOV) was attempted which improved the acidemia. The lung biopsy revealed severe fibrosis and moderate lymphocytes, consistent with a chronic process. Due to difficulty separating the patient from HFOV, airway pressure release mode of ventilation (APRV) was initiated and subsequently the patient underwent a tracheostomy on post-operative day 23. Over the next four weeks, her mechanical ventilatory support was reduced, and her trachea was successfully decannulated on postop day 52. Her arterial blood gas values (Table 1) showed little improvement over time. Similarly, a CXR obtained shortly after discharge was not much different from that obtained on the day of hospital admission and showed bilateral lung retraction (Figure 2-4). She required supplemental oxygen while asleep and with exertion and remained stable in this condition for three months at which time she underwent a double lung transplant.

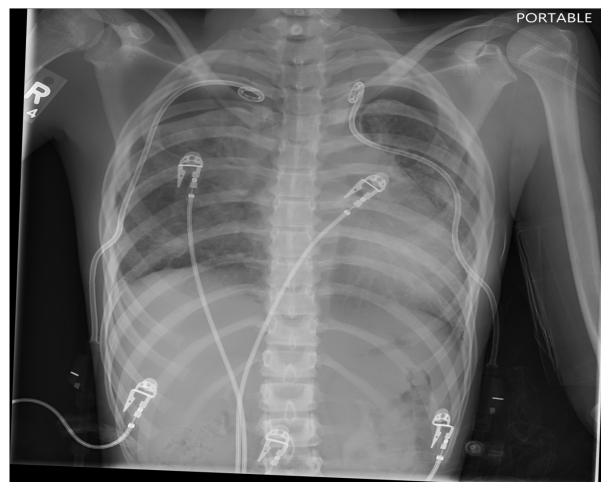


Figure 2. CXR following insertin of bilateral pigtail drains.

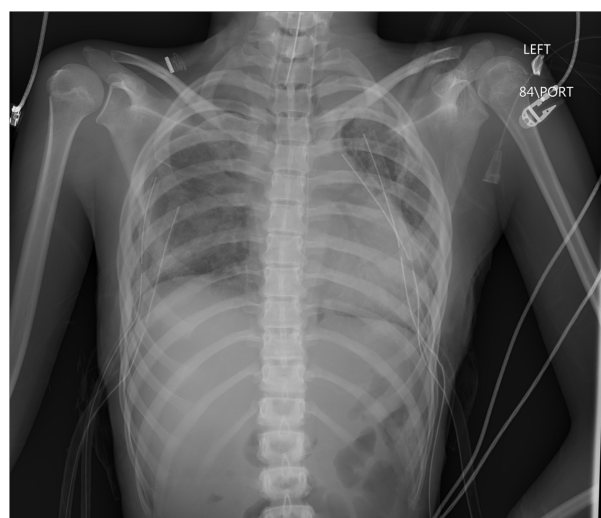


Figure 3. CXR following placement of 4 chest tubes 1 week after admission.

	Upon admission to PICU after Thoracoscopy	Shortly after initiation of HFOV	Morning of switch to APRV	After initiation of APRV	Status post Tracheostomy (on APRV)	Morning of switch to SIMV	Shortly after initiation of SIMV	Prior to Discharge
	Arterial	Arterial	Arterial	Arterial	Arterial	Venous	Venous	Venous
pH	7.13	7.23	7.47	7.34	7.36	7.30	7.31	7.47
pCO ₂	93	64	58	77	72	83	93	45
pO ₂	440	551	164	258	117	50	33	64
O ₂ Sats	100	108	100	100	98	81	57	95
Acid Base Excess	0	0.5	16.1	12.9	12.8	12.3	17.5	8
HCO ₃	31	29	42	42	41	41	47	32

Table 1. Blood gas values through hospital stay & following discharge from hospital

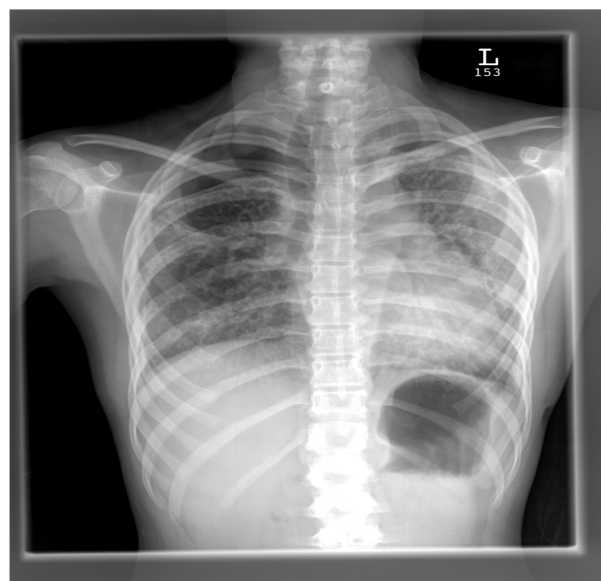

Figure 4. CXR 2 weeks post discharge.

Discussion and conclusions

We report a rare case of a child with undiagnosed severe pulmonary fibrosis who presented with symptoms and signs suggestive of spontaneous pneumothorax. Pulmonary fibrosis developed in our patient despite her not having received any of the chemotherapeutic agents that are usually associated with the development of pulmonary toxicity. i.e. bleomycin, busulfan, and the nitrosoureas (carmustine and lomustine) (3). She also did not receive radiation therapy to the thorax, which is also associated with the development of pulmonary fibrosis. As a result she was not being screened for the development of pulmonary fibrosis and had been discharged from follow-up from the long term survivor cancer clinic 4 years prior to her presentation as she had remained cancer free for 7 years. This patient was presumed to have a correctable physiologic insult (spontaneous pneumothoraces) and we were “misdirected” by that incorrect assumption as this diagnosis in and of itself does not typically result in difficulties with ventilation. The working diagnosis for this patient in the early period of admission was spontaneous pneumothorax and as such, pre-operative pulmonary function tests which would have pointed to a more significant underlying pulmonary problem were not obtained. A diagnosis or suspicion of pulmonary fibrosis by admitting physicians and consultant pulmonologists may have prepared us for earlier exploration into alternative modes of ventilation such as APRV in the peri-operative setting in anticipation of possible acute-on-chronic respiratory failure which this patient eventually manifested. However, given that the patient had not presented with symptoms previously and she had not received the chemotherapeutic agents that typically cause pulmonary fibrosis, the diagnosis of pulmonary fibrosis was not entertained until later in her hospital course.

It is not uncommon for adolescents who are dealing with chronic illnesses to develop coping strategies which may include denial and withdrawal (4, 5) which can lead to a reluctance to report (or in fact hide),

symptoms in an effort to avoid further healthcare and try to normalize the family life. In addition, families of patients with chronic illness may also be in denial of recurrence or progression of the disease. Therefore, we believe this child may have been suffering from subtle symptoms which were not relayed to her parents as they were equally surprised when the progression of their child’s disease was discussed with them. On discussion with the family after her second surgery, it was their understanding that their daughter’s asthma was mild, intermittent and unrelated to her prior cancer therapy. In addition, the patient was not being followed for pulmonary fibrosis prior to her presentation with presumed spontaneous pneumothorax. Our patient underwent two anesthetics that were marred by difficulty with spontaneous and mechanical ventilation. The double-lumen tube has been utilized historically for lung isolation in video-assisted thoracoscopy and unilateral bullous lung disease (6). Although, video-assisted thoracoscopy can be performed in children or young adults with spontaneous pneumothorax using a single lumen endotracheal tube (7). Use of the DLT was selected for this patient in order to allow for a thorough examination of both lungs and to obtain multiple lung biopsies. The clinical picture of respiratory failure following anesthesia and surgery observed in our patient has also been documented to occur in adult patients with idiopathic pulmonary fibrosis (8). Patients with idiopathic pulmonary fibrosis who undergo lung biopsy and mechanically ventilation following surgery are at increased risk for death (9). Ventilatory management of patients with pulmonary fibrosis has been described as futile and not recommended as a therapeutic or bridge maneuver for acute respiratory failure in adult patients with known disease, instead, a lung transplant is the ultimate required treatment as recovery from acute respiratory failure does not occur in adults (10). Advances in chemotherapy have improved survival rates in cancer patients but these agents affect host tissues adversely. Chemotherapy and radiation individually or in combination can result in clinically signifi-

cant pulmonary toxicity and pulmonary fibrosis. These toxic effects may be dose related but can also be enhanced by radiation (11). The chemotherapy regimen our patient received approximately 11 years earlier did not include any of these agents and she also did not receive radiation therapy to the thorax. She received cisplatin, etoposide, vincristine, cyclophosphamide, doxorubicin and ifosfamide. She was discharged from the long term cancer survivor clinic four years prior with no awareness/suspicion of chemotherapy related lung disease. The challenges observed with ventilation in our patient are akin to those observed with idiopathic pulmonary fibrosis. Acute respiratory failure in patients with idiopathic pulmonary fibrosis is associated with a poor prognosis (12,13). This holds true for pulmonary fibrosis in general. Therefore some advocate that mechanical ventilation should only be offered if lung transplantation can occur within a few days of institution of mechanical ventilation(14). Since ventilatory management of adult patients with pulmonary fibrosis has been described as futile and not recommended as a therapeutic or bridge maneuver for acute respiratory failure (10), we concur that the young age of our patient probably allowed for the successful management with mechanical ventilation albeit following an initial challenging course. This case report emphasizes the contrast between the prognosis and hospital course of our young patient and the reported prognosis in adult patients with pulmonary fibrosis and acute respiratory failure.

Pulmonary fibrosis produces lung units with significantly reduced compliance. Low compliance lung units have short time constants, and thereby inflate and deflate rapidly. This type of lung disease is typically managed by applying an open lung ventilation strategy, most commonly using conventional ventilation with small tidal volumes and positive end expiratory pressure (PEEP) in order to stent small airways and alveolar units at end expiration. The goal is to decrease shearing injuries from over distending the lung and then allowing alveolar collapse as injury occurs when collapsed lung

units are forced open (15). Our patient developed hypercarbia and required very high peak inflating pressures when conventional ventilation was initially attempted. She was converted to high frequency oscillatory ventilation (HFOV) which provides a constant high mean airway pressure that maintains patency and recruitment of alveolar units, without the shearing forces that develop during conventional ventilation from tidal opening followed by collapse. In our patient HFOV greatly improved ventilation without compromising oxygenation, probably because the higher mean airway pressure better maintained small airway patency. As her gas exchange improved on HFOV, we attempted to convert to conventional ventilation, which quickly produced severe respiratory acidemia. Transition to airway pressure release ventilation (APRV) provided a better method of weaning the patient because patients can more easily breathe spontaneously in this mode of ventilation. This mode of ventilation (APRV) is an inverse ratio, pressure controlled mode of ventilation that can be viewed as alternating levels of continuous positive airway pressure (CPAP). The upper pressure “P high” and duration of that pressure “T high” is set, and the expiratory pressure “P low” and release time “T low” is set. Spontaneous breathing can occur during and between mandatory ventilator breaths, and the P high and P low values are set by evaluating the pressure-volume curve to determine the pressures producing optimal lung compliance. All of these ventilation modes (small tidal volumes with PEEP, HFOV and APRV) attempt to produce the open lung strategy and reduce lung injury from positive pressure ventilation however, APRV was most successful because it facilitates spontaneous ventilation and improves ventilation/perfusion (V/Q) matching by improving aeration of the dorsal lung regions which reduces dead-space (16, 17). Unfortunately this mode of ventilation is not available on the conventional anesthesia ventilator hence if pulmonary fibrosis is suspected in a patient undergoing general anesthesia, smaller tidal volumes with high (PEEP) should produce optimal ventilation until

the patient is transported to the PICU where APRV mode of ventilation is available.

Pre-operative evaluation of pediatric cancer survivors usually focuses on evidence of cardiac toxicity following doxorubicin treatment or pulmonary toxicity following treatment with bleomycin, busulfan, and the nitrosoureas. This case report highlights valuable information for the anesthesiology and critical care practitioner: the possibility of pulmonary fibrosis in an adolescent cancer survivor regardless of whether the patient received the usual culprit chemotherapy agents for pulmonary toxicity should always be entertained. Heightened awareness of this possibility, will result in preparedness for acute respiratory failure during and following anesthetic exposure and will allow for the early exploration of alternative modes of mechanical ventilation. This case report also highlights the fact that acute on chronic respiratory failure in children or adolescents due to underlying pulmonary fibrosis, does not necessarily dictate a fatal prognosis as it does in adults. Lastly, the possible challenge of obtaining adequate history from a family and patient who has suffered a chronic illness in the past is also highlighted. The possibility of an underlying, severe condition should always be entertained when obtaining history from a child or family that has undergone treatment of a chronic illness in the past.

References

1. Huang TT, Hudson MM, Stokes DC, Krasin MJ, Spunt SL, Ness KK. Pulmonary outcomes in survivors of childhood cancer: a systematic review. *Chest* 2011;140:881-901.
2. Mertens AC, Yasui Y, Liu Y, Stovall M, Hutchinson R, Ginsberg J, Sklar C, Robison LL, Childhood Cancer Survivor Study. Pulmonary complications in survivors of childhood and adolescent cancer. A report from the Childhood Cancer Survivor Study. *Cancer* 2002;95:2431-41.
3. Late Effects of Treatment for Childhood Cancer. <http://www.cancer.gov/cancertopics/pdq/treatment/lateeffects/HealthProfessional/page10>.
4. Connor-Smith JK, Compas BE, Wadsworth ME, Thomsen AH, Saltzman H. Responses to stress in adolescence: measurement of coping and involuntary stress responses. *J Consult Clin Psychol* 2000;68:976-92.
5. Graue M, Wentzel-Larsen T, Bru E, Hanestad BR, Sovik O. The coping styles of adolescents with type 1 diabetes are associated with degree of metabolic control. *Diabetes Care* 2004;27:1313-7.
6. Eisenkraft JB, Cohen E, Neustein SM. Anesthesia for Thoracic Surgery. In: Barash PF, Cullen BF, Stoelting RK, Cahalan MK, editors. *Clinical Anesthesia*. 5th Edition ed. Lippincott Williams & Wilkins 2007. p. 1041-2.
7. Hau AT, Jones BA, Olutoye OA. Apical bullae and spontaneous pneumothorax. *Anesthesiology* 2013;119:201.
8. Mallick S. Outcome of patients with idiopathic pulmonary fibrosis (IPF) ventilated in intensive care unit. *Respir Med* 2008;102:1355-9.
9. Fumeaux T, Rothmeier C, Jolliet P. Outcome of mechanical ventilation for acute respiratory failure in patients with pulmonary fibrosis. *Intensive Care Med* 2001;27:1868-74.
10. Feizerfan A, Patel M, Chandan G. Mechanical ventilation for acute respiratory failure in patients with pulmonary fibrosis-yes or no. *European Journal of Anaesthesiology* 2011;28:171.
11. Abid SH, Malhotra V, Perry MC. Radiation-induced and chemotherapy-induced pulmonary injury. *Curr Opin Oncol* 2001;13:242-8.
12. Mollica C, Paone G, Conti V, Ceccarelli D, Schmid G, Mattia P, Perrone N, Petroianni A, Sebastiani A, Cecchini L, Orsetti R, Terzano C. Mechanical ventilation in patients with end-stage idiopathic pulmonary fibrosis. *Respiration* 2010;79:209-15.

13. Saydain G, Islam A, Afessa B, Ryu JH, Scott JP, Peters SG. Outcome of patients with idiopathic pulmonary fibrosis admitted to the intensive care unit. *Am J Respir Crit Care Med* 2002;166:839-42.
14. Stern JB, Mal H, Groussard O, Brugiere O, Marceau A, Jebrak G, Fournier M. Prognosis of patients with advanced idiopathic pulmonary fibrosis requiring mechanical ventilation for acute respiratory failure. *Chest* 2001;120:213-9.
15. Amato MB, Barbas CS, Medeiros DM, Magaldi RB, Schettino GP, Lorenzi-Filho G, Kairalla RA, Deheinzelin D, Munoz C, Oliveira R, Takagaki TY, Carvalho CR. Effect of a protective-ventilation strategy on mortality in the acute respiratory distress syndrome. *N Engl J Med* 1998;338:347-54.
16. Daoud EG. Airway pressure release ventilation. *Ann Thorac Med* 2007;2:176-9.
17. Modrykamien A, Chatburn RL, Ashton RW. Airway pressure release ventilation: an alternative mode of mechanical ventilation in acute respiratory distress syndrome. *Cleve Clin J Med* 2011;78:101-10.