

## Acute cerebral superior sagittal sinus thrombosis presenting with convulsive seizure in a paediatric patient

Ş. Göktürk, Y. Göktürk

University of Health Sciences, Kayseri City Hospital, Department of Neurosurgery, Kayseri, Turkey

Corresponding author: Göktürk Ş, University of Health Sciences, Kayseri City Hospital, Department of Neurosurgery, Kayseri, Turkey. Email: [suleGOKTURK@outlook.com](mailto:suleGOKTURK@outlook.com)

### Keypoints

Convulsive seizure is the most common reason for admission in the pediatric age group. In children presenting with convulsive seizures cerebral venous sinus thrombosis should be considered.

### Abstract

Cerebral venous sinus thrombosis is a rare condition. Patients often; presents with complaints such as headache, unrest and vomiting. Convulsive seizure is the most common reason for admission in the pediatric age group. A 17-year-old male patient who presented to the emergency department owing to convulsive seizure. There was not any clinical sign except papilledema. Cerebral superior sagittal venous sinus thrombosis was diagnosed with brain diffusion magnetic resonance imaging and brain magnetic resonance imaging in venography examination. Low molecule weighted heparin treatment was carried out. He was followed up in the outpatient clinic. Diagnosis of cerebral venous sinus thrombosis is difficult and early diagnosis saves lives. The reason of that cannot be found in 25% of cases. Low molecular weighted heparin treatment in sinus vein thrombosis is using as the first choice. Recommended average length of treatment period is 3-6 months for anticoagulant therapy. Early diagnosis and treatment can reduce mortality and morbidity.

### Keywords

Cerebral venous sinus thrombosis, acute convulsive seizure, pediatric cerebral sagittal sinus thrombosis.

### Introduction

Cerebral venous sinus thrombosis (CVST) is a rare terminal condition in childhood, with an incidence rate of approximately 0.4–0.7/100.0 (1). Early diagnosis is critical for reducing morbidity and mortality. Neonatal mortality associated with sinus thrombosis is 8%, and morbidity has been reported as 50% (2). In paediatric age groups, seizures are the most common medical evidence. Cases presenting with seizures and comas have worse prognoses. The most common cause of CVST in paediatric age groups is infection (3). Other causes include hypercoagulation, nephritis or nephrotic syndrome, traumatic brain injury, unspecified diseases and dehydration (4). Childhood prothrombotic genetic risk factors were found in 24–64% of cases (5). Accordingly, childhood prothrombotic genetic factors should be investigated in thrombosis cases. Early diagnosis is important in reducing morbidity and mortality. Cerebral computed tomography (CCT), magnetic resonance imaging (MRI), magnetic resonance imaging venography (MRIV), conventional angiography and Doppler ultrasonography (for newborns) are used for diagnosis. MRIV is preferred for a definitive diagnosis. A paediatric patient admitted to the hospital with acute convulsive seizure and diagnosed with cerebral sagittal venous sinus thrombosis is presented as a case.

**Case report**

A 17-year-old male patient with no known disease was admitted to the emergency department for a convulsive seizure. His general condition upon physical examination was good; he was conscious, light reflex was positive in both eyes and his neurological and other system examinations were within standard ranges. An optic examination revealed papilledema.

The patient and his family had no known history of infectious disease. His convulsions were controlled through intervention in the emergency room. The patient began levetiracetam 2 × 750 mg for maintenance therapy. Then, computerized brain tomography was taken for diagnostic purposes in the emergency department. As we examined the computerized brain tomography, we observed signal density changes, which could be compatible with thrombus, along the sagittal sinus trace and posteriorly at the confluence sinus level. The patient had no history of trauma. Next, the patient underwent brain diffusion MRI and MRIV examinations.

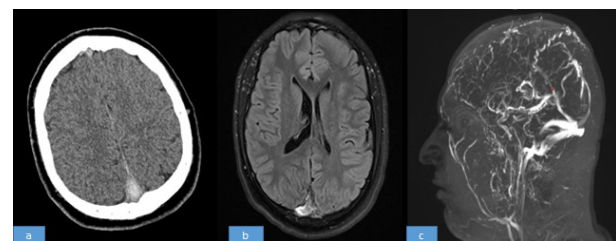
Cerebral superior sagittal venous sinus thrombosis was diagnosed using brain diffusion MRI and brain MRIV examinations (Figure 1). After diagnosis, the patient was taken to the paediatric intensive care unit for low molecular weight heparin (LMWH) treatment (0.75 mg/kg/dose, every 12 hours).

The patient underwent biochemical and molecular tests to investigate aetiology, including C-reactive protein, erythrocyte sedimentation rate, whole blood count, protein C, protein S, antithrombin 3, homocysteine, antinuclear antibody (ANA), antiphospholipid and/or anticardiolipin antibodies, lupus anticoagulant, prothrombin time (PT) and activated partial thromboplastin (aPTT) time (Table 1). He was referred to the medical genetics department for genetic investigation of factor V Leiden mutation and prothrombin 20210 gene mutation. The patient was discharged safely in a good general medical condition, with stable vital signs and no seizures. He was followed up in the outpatient clinic, and LMWH treatment

continued at a maintenance dose (6,000 IU every 12 hours) for 3–6 months.

ANA	Lupus A.	MPO ANCA	Anti ds-DNA	ε-ANCA	IgE	C3c	C4	D.Coombs	Homocystein
-	<1,2	-	+	-	244	2,07	0,41	-	14,2
Anti β2 Glicoprotein	Antithrombin 3	Protein C	Protein S	PT	APTT	INR	CRP	LDH	CK
-	93	91	70	14,3	24,9	1,08	7,3	267	250
Sedimentation	WBC	Hgb	HCT	PLT					
4	8150	15,6	46	258000					

**Table 1:** Biochemical and molecular tests were applied.



**Figure 1a:** A CT scan before treatment showing a high-density shadow at the confluence sinus level (delta sign).

**Figure 1b:** T1 MRI image; diffuse meningeal enhancement, superior sagittal sinus thrombosis indicator (delta sign).

**Figure 1c:** Sagittal section of MRI venography, thrombosed superior sagittal sinus, without blood filling.

**Discussion**

Although the clinical manifestations of CVST can vary, the most common symptoms are seizures, confusion, headache, focal neurological findings and cranial nerve palsy. Diagnosis is difficult, but early diagnosis saves lives. The risk factors are perinatal complications in the neonatal period and hypoxia, head and neck infections in preschool children, otitis media, sinusitis and mastoiditis (6). In 25% of cases, no specific cause was found (7). LMWH is the first choice of treatment for sinus vein thrombosis. The average recommended treatment period for anticoagulant therapy is 3–6 months (8).

Unver et al. studied 11 paediatric patients with CVST (5). They found that venous sinus thrombosis was common in males, and the average age of onset was 14. They stated that headache was the most common reason for admission, followed by double vision. In all but one patient, Unver et al. diagnosed papilledema, and papilledema was also detected in our case. In their study, a two-year-old

patient had a convulsive seizure and was diagnosed with CVST after trauma. In infants and young children, seizures and focal signs have been reported more frequently in the literature, whereas headaches have been reported more frequently in older children. Although the literature has reported sagittal sinus thrombosis as the most common thrombus type, Ünver et al. found that transverse and sigmoidal sinus thromboses are the most common (5,9). Wang et al. evaluated paediatric patients with CVST in a 30-study series (4), and the clinical manifestations included headache (89%), vomiting (73%) and visual symptoms (41%), including blurred vision, blindness, double vision, swollen eyelids and eye pain accompanied by protrusion. The median age was 8.33 years. The median CVST duration was 14 days, and only 10 patients were diagnosed within 7 days of onset. There were 15 superior sagittal sinus thrombosis cases, 2 inferior sagittal sinus cases, 12 left transverse sinus cases, 14 right transverse sinus cases, 7 left sigmoid sinus cases, 9 right sigmoid sinus cases, 6 straight sinus cases, and 1 cavernous sinus case. All patients underwent LMWH anticoagulant therapy (90 IU/kg/dose subcutaneously, twice daily). They had diagnosed only 10 cases early, within 7 days of onset. This disease's morbidity is high in actual clinical practice. CVST may present with an acute, subacute or chronic onset. In the literature, an uncharacteristic headache is a common clinical symptom, and 90% of patients experience headaches (10). In our case, a 17-year-old male patient presented to the emergency department for a convulsive seizure. After radiological imaging and diagnosis, the patient began LMWH and tests were performed to investigate aetiology. After completing the in-hospital treatment and being discharged, intermittent outpatient follow-up management of the patient began.

### Conclusion

In children presenting with convulsive seizures, CVST should be considered. Early diagnosis and treatment of this disorder might reduce morbidity and mortality. Anticoagulant therapy for sinus vein thrombosis is many clinicians' first treatment choice.

*Göktürk et al. Acute cerebral superior sagittal sinus thrombosis*

### References

1. Swaiman FK, Ashwal S, Ferriero DM, Schor NF. Swaiman's Pediatric Neurology Principles and Practice 5th ed. 2012:1395- 436.
2. Wasay M, Dai AI, Ansari M, Shaikh Z, Roach ES. Cerebral venous sinus thrombosis in children: a multicenter cohort from the United States. *J Child Neurol* 2008;23:26-31.
3. Sebire G, Tabarki B, Saunders DE, Leroy I, Liesner R, Saint-Martin C, Husson B, Williams A N, Wade A, Kirkham FJ. Cerebral venous sinus thrombosis in children: Risk factors, presentation, diagnosis and outcome. *Brain* 2005;128:477-89.
4. Xin-Hua Wang, Lin-Mai Zang, Yi-Ming Chai, , Ji Wang, Li-Fei Yu, Shui-Zhen Zhou. Clinical Characteristics and Outcomes of Pediatric Cerebral Venous Sinus Thrombosis: An Analyses of 30 Cases in China. *Frontiers in Pediatrics* September 2019; 7:Article 364.
5. Ünver O, Ekinci G, Kutlubay BI, Gülten T, Güneş S, Hacifazlıoğlu NE, Türkoğan D. Evaluation of cases with cerebral thrombosis in children. *Turkish Archives of Pediatrics* 2016;51: 87-93.
6. Hedlund GL. Cerebral sinovenous thrombosis in pediatric practice. *Pediatr Radiol* 2013;43:173-88.
7. Stam J. Thrombosis of the cerebral veins and sinuses. *N Engl J Med* 2005;352:1791-8.
8. Lebas A, Chabrier S, Fluss J, Gordon K, Kossorotoff M, NowakGöttl U, Vries LS, Tardieu M, French Society for Paediatric Neurology/ European Paediatric Neurology Society guideline on the anticoagulant treatment of cerebral sinovenous thrombosis in children and neonates. *Eur J Paediatr Neurol* 2012;16:219-28.
9. Menascu S, Lotan A, Ben Zeev B, Nowak-Gottl U, Kenet G. Cerebral venous thrombosis in the Mediterranean area in children. *Mediterr J Hematol Infect Dis* 2011;3(1):e2011029.
10. Ferro JM, Canhao P, Stam J, Bousser MG, Barinagarrementeria F, ISCVT Investigators. Prognosis of

cerebral vein and dural sinus thrombosis: results of the International Study on Cerebral Vein and Dural Sinus Thrombosis (ISCVT). *Stroke* 2004; 35:664–70.