

Surgical treatment of familial adenomatous polyposis (FAP) of the colon on children

M.U. Ismayilov¹, R.Sh. Polukhov¹, I.V. Poddubny²

¹Pediatric surgery department of Azerbaijan Medical University, Baku, Azerbaijan

²Yevdokimov Moscow Medical-Stomatological University, Baku, Azerbaijan

Corresponding author: E. M. Nasibova, Azerbaijan Medical University, Baku, Azerbaijan.

Email: doc.nasibova.esmira@gmail.com

Keypoints

Endosurgical technology is less traumatic and is accompanied by less blood loss, significantly reduces the duration of intensive care in a specialized department, the severity of postoperative pain, the earlier start of enteral load and faster recovery of peristalsis.

Abstract

The article analyzed the anamnesis of 46 children treated for familial adenomatous polyposis of the large intestine from 2010 to 2022 (12-year period) in pediatric surgery departments. The presented work is a cohort retrospective scientific-research work, the main indicators of which have been completed since 2010 with a prospective examination. Surgical treatment for confirmed familial adenomatous polyposis of the large intestine was carried out in a planned manner, but before that, preoperative diagnosis, confirmation, and observation with control examinations were carried out for a long time. In all cases, the scope of the operation was completed with total proctocolectomy, ileoanal anastomosis (with or without a protective stoma). Analyzing our experience of treating 46 children with FAP using laparoscopic (in 34 patients) and "open" methods (in 12 children), we believe that the technique of laparoscopic total proctocolectomy developed and applied in our clinic and performed with direct ileoanal anastomosis is effective in this serious disease. is an effective treatment method. Universality, convenience, radicality, etc. it does not lag behind "open" operations in any aspect. Such laparoscopic operations on the large

intestine can be carried out in clinics with sufficient experience in that field, with all the necessary equipment, instruments, devices and consumables, as well as with the participation of specialists in related specialties who are usually engaged in the monitoring and treatment of such diseases.

Keywords

Adenomatous polyposis, laparoscopy, ileoanal anastomosis, protective stoma.

Introduction

Familial adenomatous polyposis (FAP) of the large intestine belongs to genetically determined multitumor syndromes, which represents a distinct group of diseases characterized by polyps in the gastrointestinal tract [1,2,3,4]. YAP is autosomal dominant (APC/MutY) and is characterized by the formation of hundreds to thousands of adenomas in the colon and rectum, often in the small intestine and stomach [5]. Diffuse polyposis of the colon is a serious systemic disease. Multiple polyps affect the mucosa of all parts of the colon. Malignant transformation of polyps is practically not observed in children [6,7]. However, the disease is progressive and causes permanent blood loss, anemia, protein and other metabolic disorders that adversely affect the developing

body, which inevitably leads to delayed physical development and disability. In addition, it leads to irreversible changes in homeostasis after the patient reaches adulthood, as well as the danger of polyps becoming malignant [8]. According to many researchers, cancerous transformation of polyps is observed in almost 100% of cases in adult patients [9].

It should be noted that 44 (95.7%) of our patients have a clear family history - one of the parents suffered from this disease and its consequences or died from oncological complications of YAP. In these children, the screening diagnosis of the condition of the large intestine was started as early as possible (their first colonoscopy was performed at the age of 4-7), timely detection and confirmation of the diagnosis, and early enough decision to perform "prophylactic" radical surgery.

Material and methods

The main clinical group of the study (group 1) included 34 children who underwent surgical treatment with the laparoscopic technique developed in the clinic. 20 of them were boys (58.8%), 14 were girls (41.2%). The age of the children varied from 9 to 17.

Comparative group 2 in our study included 12 children with YAP, for whom the previously accepted common "open" surgical methods, wide laparotomy approaches were used during radical surgery. Out of 12 patients involved in treatment, 7 were boys (58.3%), 5 were girls (41.7%). For all patients in group 2, surgical intervention includes the following stages:

This age distribution of patients with hereditary adenomatous polyposis of the colon was related to the characteristics of the onset, course, diagnosis and observation of the disease in children. It should be noted that the age of 9 and older during YAP is considered the optimal time for surgical treatment in terms of prevention of malignant diseases.

The main clinical signs of the disease in children were as follows: episodes of bleeding from the large intestine - 38 (82.6%) children, diarrhea mixed with mucus and blood - 13 (28.3%) children, serious retardation in physical

development - 8 (17.4%) child, episodes of pseudomembranous colitis formed against the background of *Clostridium difficile* contamination - 6 (13%) children, severe colitis accompanied by toxic dilatation of the colon and eliminated by conservative measures - 2 (4.3%) children.

Planned endoscopic examinations (FEGDS + ileocolonoscopy) were performed at least once every 6-12 months with the description and documentation of their results, as well as comparative analysis of the state of the intestine in dynamics as much as possible. Complex morphologic studies were performed with routine biopsies by removing the largest growths, including determining the signs and extent of dysplasia. In 13 children, signs of mild or moderate (LOW GRADE (LGD)) dysplasia were identified during observation, no confirmed malignant tumors were detected. All patients with suspected YAP underwent a molecular genetic blood test for the presence of mutations in the APC/MutYH genes, which is necessary for the final confirmation of the diagnosis and, in many cases, mainly to determine the further tactics of observation and treatment. X-ray contrast studies were included in the examination of the intestines in all cases, MR enterography was performed in 32 (69.6%) patients, video capsule endoscopy was performed in 12 (26.1%) patients, and as a result, in 16 (34.8%) children, duodenum or other small intestine was diagnosed. single or several polyps were identified. The duration of pre-operative observation of children diagnosed with YAP ranged from 2 to 8 years (3.9 years on average).

In the pre-operative period, all children of the 1st group were supplemented with previously conducted examinations and prepared for surgical intervention: Standard general clinical, biochemical and other analyses, assessment and correction of the nutritional status of patients, test for *Cl Difficile* toxins, if detected, pre-operative decontamination is carried out, abdominal cavity, pelvis, retroperitoneal area, etc., a comprehensive ultrasound examination, preparation of the intestines for

surgery was carried out as a preparation for colonoscopy, all additional laboratory, instrumental examinations and consultations related to the identified pathologies of other organs and systems were carried out, and also the anesthesiologists performed general anesthesia more safely those necessary for their conduct have been determined. It should be noted that surgical treatment for confirmed familial adenomatous polyposis of the large intestine is carried out in a planned manner and is almost always preventive in nature due to the high probability of turning into malignant tumors.

All children of the 1st group underwent radical operations using laparoscopic methods. Laparoscopic access is a very suitable tool for performing such interventions. The essence of the operation to be performed in children should be complete and radical removal of the entire large intestine, including the rectal mucosa. Here we will highlight only the tactical and technical points that are important from our point of view in the case of familial adenomatous polyposis of the colon:

The operation on the child is carried out by two surgical teams in the position of lying on the back, the lower limbs are separated and fixed on the operating table. Laparoscopically, the entire large intestine is mobilized, including the rectum as well as the distal part of the small intestine. All ligaments and mesentery of the large intestine are cut, and the musculature of the small intestine is carefully mobilized to ensure that the loops are lowered into the perineum without tension. With partial restoration of the transition layer of the peritoneum, additional fixation of the descended ileum to the parietal peritoneum of the pelvis is performed (Fig. 1).

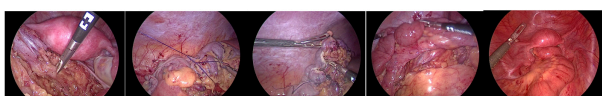

Figure 1. Laparoscopic mobilization, transection, and resection of the colon.

From the side of the perineum - transanal dissection of the mucous membrane of the entire rectum is carried out starting immediately behind the tooth line, but it is carried out with its mandatory protection. A serous-muscular cylinder approximately 3-5 cm long is created, through which the laparoscopically mobilized large intestine and the distal part of the small intestine are lowered into the space. Here, the small intestine is attached to the muscles of the pelvic floor, cut and a direct ileoanal anastomosis is formed, transanal intubation of the anastomosis and the small intestine is performed (Fig. 2).

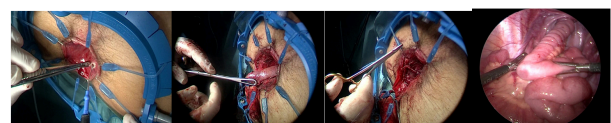


Figure 2. Initiation of dissection of the mucosa over the serrated line, retraction of the small intestine and formation of the ileoanal anastomosis, transanal intubation of the anastomosis and small intestine.

The removed large intestine was sent for histological examination in all cases, the established diagnosis was fully confirmed (Figure 3).

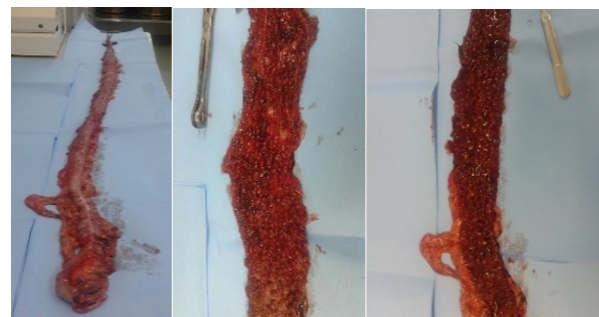

Figure 3. The large intestine has been completely removed. View of the preparation in its entirety and in the opened state. Sometimes the number of polyps in the intestinal tract exceeds fifty thousand.

The issue of the necessity and feasibility of protective ileostomy with temporary closure of the distal intestine and ileoanal anastomosis was decided based on the presence of any technical difficulties in isolating, mobilizing, lowering the distal part of the small intestine, forming the ileoanal anastomosis, as well as detecting inflammatory changes in the abdominal cavity and pelvis. Any suspicion of these reasons is considered an indication for the placement of a protective ileostomy in

the right hip region. Protective ileostomy was applied in 10 patients (29.4%).

Total proctocolectomy with ileo-anal anastomosis was performed in the patients included in the 2nd group using a wide median laparotomy. Protective ileostomy was placed in 5 patients.

Standard care for patients after surgery includes: Treatment in the intensive care unit and intensive care unit for 2-3 days after surgery. In all cases, epidural anesthesia was performed for 2-3 days. 12 hours after the operation enteral load starts with water, 24 hours after the operation - a food mixture is given, on the 5th-6th day a gradual but rapid expansion of nutrition to normal food is carried out. 10 days of strict bed rest and 5-7 days of antibacterial therapy are carried out.

As one of the important elements to prevent the possible failure of the ileo-anal anastomosis, the intubator-tube is kept in the lowered bowel for 3-5 days, which is important to avoid the very undesirable delay in the passage of stools and gases in the early postoperative period.

In the subsequent period, rectal control examinations were carried out: once a week for a month, then once a month for 6 months, then once every 3 months for a year. If an ileostomy is placed, the stoma is closed after complete healing of the anastomosis, usually 3-6 months after the radical operation, a mandatory examination (except for anastomotic failure and leakage of contrast fluid).

In the postoperative period, observation and treatment by a gastroenterologist and other specialists is continued. It is especially necessary to emphasize the necessity of mandatory inclusion of fecal thickeners, as well as drugs that reduce small intestinal peristalsis - loperamide in individually selected doses, in the complex postoperative treatment of children with CKD.

This allows to radically change the postoperative recovery period in children who have undergone proctocolectomy and prevent unpleasant complications associated with the absence of a large intestine.

Observation and conservative treatment of operated children is continued by gastroenterologists, surgeons and other related specialists throughout childhood - until the patient is transferred to the medical network of adults.

Results

W (Wilcoxon-Manna-Whitney) criterion was applied in the development of quantitative indicators during the statistical analysis of the research results. In the analysis of quality indicators, Pearson's C2 (chi-square) criterion (when $n \geq 5$) and Fisher's Exact Method (when $n < 5$) were applied. Statistical studies were conducted using MS EXCEL and S-PLUS programs. Comparative analysis of treatment outcomes.

In order to evaluate the effectiveness of the treatment of patients with YAP in the main and comparative groups, the following intraoperative and postoperative indicators were analyzed: the duration of the surgical operation, the volume of intraoperative blood loss, the frequency and severity of intraoperative complications, the need and frequency of conversion (for laparoscopic operations), resuscitation and intensive care the necessity and duration of stay in the department, the period of normalization of body temperature, the necessity and duration of using painkillers (narcotic, non-narcotic, etc.), the necessity and duration of stimulation of the intestines with drugs, as well as the time for the recovery of intestinal peristalsis, the patient's activation time, the patient's stay in the hospital after surgery duration, frequency and severity of early and late postoperative complications, frequency of repeated surgical operations due to complications, functional and cosmetic results of treatment in the near and long term, quality of life of operated patients (table 1). The results of the treatments performed on our patients are presented in the following tables.

Compared indicators	Main group 1, n=34	Comparison group 2, n=12	p
Operation duration (min.)	130,1±5,5 (80-195)	136,3±11,9 (85-210)	p>0,05
Volume of intraoperative blood loss (ml)	53,9±1,5 (40-70)	216,3±4,5 (190-240)	p<0,001
Frequency of blood transfusion (intraoperative and postoperative)	–	–	–
Frequency of conversion (for group 1)	–	–	–
Length of stay in intensive care unit (days)	1,94±0,15 (1-3)	3,58±0,36 (2-5)	p<0,001
Time frame for normalization of body temperature (days)	3,62±0,13 (3-5)	5,42±0,23 (4-6)	p<0,005
Duration of use of painkillers (days)	4,06±0,13 (3-5)	6,92±0,36 (5-8)	p<0,001
Duration of drug stimulation of the intestines (days)	2,32±0,08 (2-3)	4,83±0,32 (3-6)	p<0,001
Postoperative enteral loading time (hours)	16,82±0,59 (12-24)	26,75±0,54 (24-30)	p<0,001
Time to appearance of loose stools (days)	1,88±0,14 (1-3)	3,33±0,22 (2-4)	p<0,001
Bed days of the patient in the hospital after surgery	10,18±0,19 (8-11)	16,17±0,30 (14-17)	p<0,001

Table 1. Comparison of intraoperative indicators characterizing laparoscopic and "open" operations.

The analysis of the results of surgical treatment of children was carried out both in the early period (within 30 days after the intervention) and in the long postoperative period (from 1 to 12 years). We used the indicated classification (based on the Clavien–Dindo scale) to assess the severity of early postoperative complications.

Groups of FAP patients	group 1, n=34		group 2, n=12		P
	absol.	%	absol.	%	
Total early postoperative complications	5	14,7	5	41,7	p<0,05
Degree of complications (according to Clavien-Dindo scale)					
Grade 1 (prevented wound infection)	1	2,9	2	16,7	P>0,05
Grade 2 (adjunctive drug therapy and other therapies)	1	2,9	1	8,3	P>0,05
Grade 3a – interventions without general anesthesia	–	–	–	–	–
Level 3b – interventions under general anesthesia	2	5,9	1	8,3	P>0,05
Grade 4 – additional treatment of complications in the intensive care unit	1	2,9	1	8,3	P>0,05
Grade 5 – patient death.	–	–	–	–	–

Table 4. Early postoperative complications in operated patients.

It should be emphasized that all complications requiring reoperation (partial failure of ileoanal anastomosis, application of ileostomy and additional medication and local treatment) were observed in children operated without protective ileostomy (a total of 3 children – group 1 – 2 patients, 2 in group - 1 patient). Taking this into account, we have changed surgical tactics in recent years - all patients undergoing laparoscopic surgery for adenomatous polyposis of the large intestine are subjected to an ileostomy for 3-4 months until the ileoanal anastomosis is completely healed at the end of the operation.

The cosmetic results of the treatment were subjectively evaluated by patients and their parents in response to

questionnaires, for example: good, the results are completely satisfactory, they do not cause any discomfort in everyday life. Sufficient, without any physical discomfort or aggravation, from time to time to conduct, dress, etc. the presence of elements of psychological dissatisfaction that have an impact. Inadequate, along with psychological dissatisfaction, there are physical concerns that affect lifestyle and physical activity from time to time, and there are plans for cosmetic correction in the future.

Evaluation of cosmetic results	Main group 1, n=34		Comparison group 2, n=12		P
	absolute	%	absolute	%	
Good	31	91,2	6	50,0	P=0,005
Enough	3	8,8	5	41,7	P=0,02
Insufficient	0	–	1	8,3	P>0,05

Table 5. Evaluation of cosmetic results of treatment in laparoscopic and "open" groups.

Conclusion

When conducting a comparative analysis of the use of laparoscopic and "open" methods for performing proctocolectomy during YAP, we can come to the following conclusion. Endosurgical technology is less traumatic and is accompanied by less blood loss, significantly reduces the duration of intensive care in a specialized department, the severity of postoperative pain, the earlier start of enteral load, the faster recovery of peristalsis and intestinal passage, the time of patients' stay in the hospital, as well as reduces the rehabilitation period of patients in the early and long postoperative periods (p<0.001, p<0.005), is accompanied by a slight decrease in the number of early postoperative complications (p<0.05), ensures an undoubted improvement in the cosmetic results as assessed by the patients themselves and their parents does (P=0.005).

Thus, the described algorithm for the two-stage endosurgical treatment of children with YAP can be the method of choice in this difficult and responsible group of patients, combining the following: minimal trauma, radicality, reliability in terms of postoperative complications, maximum compliance with the principles of cancer prevention. Laparoscopic operations can be used as a radical surgical treatment method for familial

adenomatous polyposis of the colon. Endosurgical stoma operations, total proctocolectomy, lowering of the ileum by creating an ileoanal anastomosis are effective and safe treatment methods for patients in these complex groups.

References

1. Kazubskaya T.P., Belev N.F., Kozlova V.M., et al. Hereditary syndromes associated with polyps and the development of malignant tumors in children. *Oncopediatrics*. 2015; 2 (4): 384–395.
2. Sichinava I.V. Diffuse family polyposis in children. *Experimental and Clinical Gastroenterology*. 2018;(1):p.61-67. (In Russ.)
3. Cohen S, Gorodnichenco A, Weiss B, et. al. Polyposis syndromes in children and adolescents: a case series data analysis. *Eur. J. Gastroenterol. Hepatol*. 2014; 26 (9): 972–977.
4. Ghadamyari F, Heidari MM, Zeinali S. et. al. Mutational screening through comprehensive bioinformatics analysis to detect novel germline mutations in the APC gene in patients with familial adenomatous polyposis (FAP). *J. Clin Lab Anal*. 2021 May;35(5):e23768. doi: 10.1002/jcla.23768. Epub 2021 Mar 26.PMID: 33769591
5. Knedy RD, Potter DD, Moir CR, et. al. Polyposis syndromes in children and adolescents: a case series data analysis. *Eur. J. Gastroenterol. Hepatol*. 2014; 26 (9): 972–977.
6. Stone JK, Bernstein CN, Singh H. et. al. Prevalence of Gastroduodenal Polyps in Children With Familial Adenomatous Polyposis. *J Can Assoc Gastroenterol*. 2020 Dec 24;4(5):e101-e109. doi: 10.1093/jcag/gwaa040. eCollection 2021 Oct.PMID: 34617007.
7. Lapteva E.A., Kozlova I.V., Myalina Yu.N. And. et.al. Colon polyps: epidemiology, risk factors, diagnostic criteria, management tactics (review). *Saratov scientific and medical journal*. 2013; (2): 252–259.
8. Aghabozorgi AS, Bahreyni A, Soleimani A. et. al. Role of adenomatous polyposis coli (APC) gene mutations in the pathogenesis of colorectal cancer; *Ismayilov et al. Adenomatous polyposis in children*

current status and perspectives. *Biochimie*. 2019 Feb;157:p. 64-71. doi: 10.1016/j.biochi.2018.11.003. Epub 2018 Nov 8.PMID: 30414835